

Operations

The main repair is called a Pull-through or PSARP (Posterior-Sagittal-Anorectoplasty) and it is usually performed within the first year of life. This operation generally takes 3-5 hours, with a post-operative stay of 5-7 days.

Cloaca which is a more complex defect requires a PSARVUP (Posterior-Sagittal-Anorectovaginourethroplasty) and usually requires a longer stay and additional recovery time.

Dilatations

Two weeks after the pull-through surgery, you may begin a program of anal dilatations in order to stretch the child's new anus to a normal size. You will begin with a dilator that fits snugly, and perform the dilatations twice a day. Every 1-2 weeks the size of the dilator will be increased until the correct size is reached. At this point the colostomy can be closed. The dilatations continue, but the frequency is gradually decreased until they are no longer required.

Colostomy Closure and Nappy Rash

Usually, within 2-3 months of the main repair (PSARP or PSARVUP) or adequate dilatation is achieved the colostomy is closed. This operation usually requires a stay of 5-6 days. Throughout this stay, baby will start passing stool through the new rectum for the first time and they will be frequent and loose. During this time, they are susceptible to severe nappy rash and good bottom care is required with the use of a skin barrier cream.

There are a variety of barrier creams available and it may take some trial and error to find one that works well for your baby. Please ask your nurse for some advice.

It is advisable to start preparing baby's "bottom" a week/fortnight prior to this operation. This can be done by placing some stool from baby's colostomy onto the nappy and having baby wear the nappy for 5-10 mins, and/or applying 'skin prep' wipes to baby's bottom. This should be done several times a day.

Glossary

Anorectal – pertaining to both the anus (ano) and the rectum (rectal)

Congenital anomaly – an abnormality present at birth

Cloaca – malformation where the colon, bladder and vagina connect to a single passageway opening out of the perineum

Fistula – an abnormal passage from a normal cavity to the body surface or another cavity.

Genitourinary tract – organs and parts concerned with the kidneys, urinary bladder, and reproductive organs (vagina, uterus, testes etc)

Perineum – the outer area between the vulva and the anus in a female or between the scrotum and anus in a male.

Adapted from 'Anorectal Malformations' by the Pullthru network.
www.pullthrough.org

Disclaimer: Due to the dynamic state of the internet we cannot recommend or endorse this website.

Parents Support Group

Bowel Group for Kids Inc.

P.O. Box 40

Oakdale NSW 2570

Ph: 02 4659 6186

Note: This is general information only and the situation can vary from case to case.



Compiled by J Rowe Surgical Nurse Specialist

Department of Paediatric Surgery
Starship children's Hospital
Level 4
Phone 64 9 307 4949 ext. 6381



SSH/WI-3033/007 – updated 01/06



Anorectal Malformations

A Parent's Guide

Department of Paediatric Surgery
Starship Hospital
Auckland

SSH/WI-3033/007 – updated 01/06

SSH/WI-3033/007 – updated 01/06

Introduction

Your baby has been born with an anorectal malformation. This brochure is intended to provide general information about anorectal malformations and the operations that are done to deal with it.

What are Anorectal Malformations?

The term 'anorectal malformation' encompasses a wide range of congenital anomalies involving the rectum, urinary and reproductive structures with varying degrees of complexity. These are usually referred to as low or high.

Most babies born with anorectal malformations have no anal opening and may have an abnormal connection between the rectum and the genitourinary tract or the perineum. This abnormal connection is called a fistula.

In females, who have a connection between the rectum, urinary and reproductive tract the word "cloaca" is used.

The type of malformation will influence what surgery baby may require. It will also influence the outcome for your child's bladder and bowel control.

Background/Incidence

Imperforate anus has been a documented anomaly since antiquity. It has an incidence of 1 in 4000 newborns. Cloaca has an incidence of 1 in 50 000.

Anorectal malformations affect all racial, social, cultural and economic groups equally. Studies have not found any definite causes for these birth defects, which are thought to develop during the 4th to 12th week of gestation.

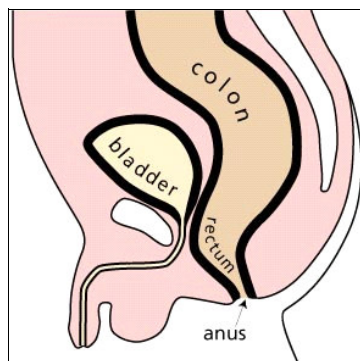
Associated Defects

There are a number of associated defects that are commonly found in a child born with an anorectal malformation.

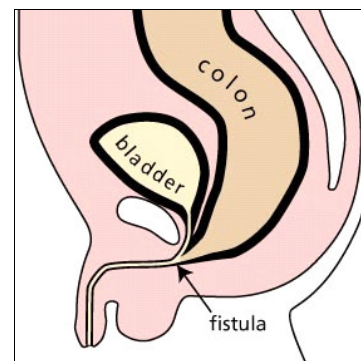
Defects of the urinary tract are the most common, and may require immediate attention.

Other defects which may be present involve the vertebra (spine), anus, heart (cardiac), trachea, oesophagus, renal and limb. This combination of defects is termed **VACTERL**.

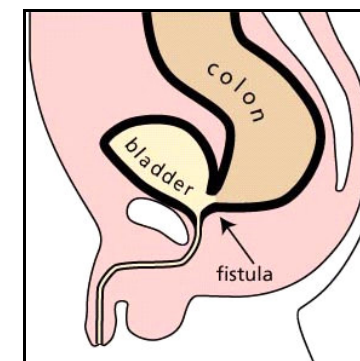
The severity of these defects vary and your baby will be investigated for these defects. If present they will be treated as required.



Normal male anatomy



Recto urethral bulbar fistula (Low)



Recto bladder neck fistula (High)

Colostomy

There is a large spectrum of defects and each one is different from the other. However, there are certain categories or types of defects with similar prognoses and management.

Babies born with a very "low" defect typically require a simple operation soon after birth. These children have a good prognosis for bowel control.

Babies born with a "high" defect require more complex treatment. This usually begins with a temporary colostomy on the first day of life. A colostomy is created by dividing the large intestine and then bringing the two ends through the abdominal wall. This procedure provides the child with a temporary way to pass stool.

Colostomy Care

The usual time between the initial colostomy and the repair surgery is between 3-12 months, but may be longer.

Since you are dealing with a small baby, there may be some

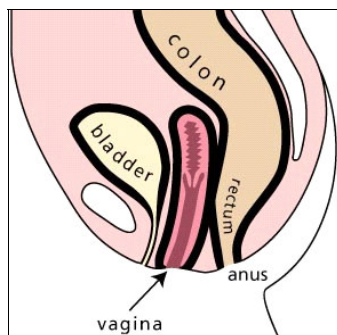
trial and error in handling the ostomy products. You will be provided with help from a stoma therapist and the nurses on the ward.

A referral will be made to a community stoma therapist for ongoing help, when you and your baby are discharged home.

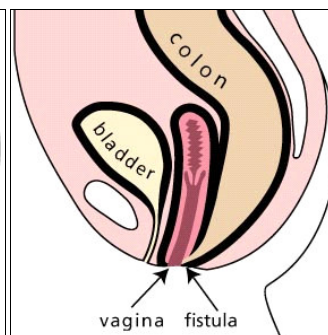
Distal Colostogram

Prior to the pull-through operation (main repair), it is important to determine the precise defect your baby was born with. This will help in terms of prognostic and therapeutic implications, as well as helping the surgeon to visualise the baby's anatomy.

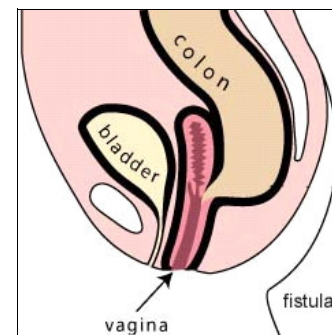
The distal colostogram is the best study for this, and it consists of injecting contrast material into the distal stoma (closest to the anus) to show the characteristics of the baby's specific defect. This will show the surgeon how high the rectum is and if there is a fistula connecting to the urinary tract.



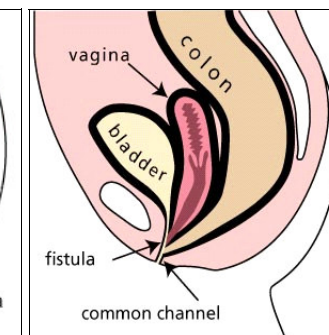
Normal female anatomy



Vestibular fistula



High Imperforate anus



Typical Cloaca